

Early myofunctional approach to skeletal Class II

C. Quadrelli
M. Gheorgiu
C. Marchetti
V. Ghiglione

University of Studies of Milan
Clinic of Odontology and Stomatology
Institutes of Clinical Professional
Specialization
Director: Professor F. Santoro
Division of Clinical Orthognatodontics
And Electromyography
Head of Department: Professor V. Ghiglione

Introduction

Therapy aimed at skeletal Class II subjects is carried out at the Odontology Clinic of Milan University in accordance with studies conducted by Petrovic and Stutzmann (12, 13), with an initial orthopaedic phase focussing on condylar growth. Such a therapeutic phase is made to coincide with the peak of pre-pubertal growth, which we have identified by evaluating skeletal age by X-raying the wrist and hand, following the method according to Gianni (5). This is performed for the purpose of obtaining the greatest possible growth period, coupled to an acceptable duration of therapy.

This ideal age to start treatment corresponds, in our studies, to nine years of age plus or minus one year. Younger children also come to be observed, mainly through the screening visit that they undergo at about six years of age (the onset of change of dentition). During this phase, although treatment is mainly directed towards identifying cross-over bite and resulting asymmetries (interceptive orthodontics), a large number of skeletal Class II children are noticed whose orthopaedic therapy is postponed until they reach nine years of age. A large



Key Words:

Skeletal Class II
Early treatment
Soft tissues dysfunctions

Abstract - Early myofunctional approach to skeletal Class II

We analysed the effects of the Pre-Orthodontic Position Trainer in skeletal development, muscle function, tongue function, breathing and bruxism in skeletal Class II patients. This one-year therapy prepares for usual orthopaedic Class II treatment in patients with soft tissue dysfunction or bruxism and should be adopted before peak pre-pubertal growth; the ideal age is 4 - 9 years.

The results of the treatment were analysed by means of clinical, radiological, electromyographical, kinesiographical, stabilimetric and rhinomanometric evaluations and the measurement of arch diameter using plaster models. The cases described in this pilot study demonstrate the efficiency of this early myofunctional therapy in patients in skeletal Class II.

number of skeletal Class II dismorphosis also displays disorders or parafunctions of the soft tissues of the stomatognathic apparatus.

These cases have been classified into two reasonably homogenous groups:

- the first, Group A, is characterised by: skeletal Class II, dentoalveolar open bite, lingual malposition and atypical deglutition;
- the second, Group B, is characterised by: skeletal Class II, dentoalveolar deep bite and bruxism.

Both groups are composed of patients with non-obligatory oral respiration.

It was decided to subject these two groups to early pre-orthopaedic treatment aimed at resolving dysfunctions through gentle, but active, inducement of the protruding mandibular position (14, 15). Our aim was that of evaluating with *ex adiuvantibus* criteria the clinical efficacy of this early intervention, to which this pilot report refers.

In future, these patients will be compared, for evaluation purposes, after classic orthopaedic Class II treatment, with patients having received only Class II orthopaedic treatment at the age of nine, plus or minus one year. The purpose of this practice is to also evaluate statistically and not only from a clinico-empirical point of view, the efficacy of this early therapeutic approach.

At the same time, the purpose of this preliminary report is to highlight possible relationships between skeletal Class II, dysfunctions of the soft tissues, parafunctions, oral respiration and the general posture of the subject.

Electromyography, Stabilimetry, Rhinomanometry

A qualifying characteristic of the approach to orthodontic patients is that of defining a diag-

nosis and treatment plan, with particular reference to function, while considering dentition not only within the mouth, but also in relation to other organs and systems, in adherence to Gianni's indications (5), so to follow a holistic approach to the patient. For this reason, we consider appropriate the use of electromyography, stabilimetry and rhinomanometry, particularly during the patient's growth period when the correct relationship between the various systems acquires significant importance in the control of growth of the stomatic structures (10).

The balanced development of the transverse diameter of the upper jaw, for example, is positively influenced by correct nasal respiration (16), hence the necessity of evaluating this function through rhinomanometry.

A properly designed therapeutic plan should thus take into account the possible need to reprogram respiration from oral to nasal.

Muscles inserted into the maxillary bone must function correctly for normal development of this bone. The active movement of the mandible by the external pterygoid muscles is determined by activating condylar growth (12). Electromyography allows detection of possible muscular malfunctions and putting corrective treatment into place. Furthermore, electro-myography allows to determine whether a brace to correct the mandibular position stimulates the external pterygoid muscles and whether it will be useful in encouraging condylar growth.

Stabilimetry allows the detection of overall postural improvements whenever an intervention is made to regularise the balanced growth of the maxillaries.

It is also quite probable that the correction of oral respiration could contribute, by normalis-

ing the function of the relevant muscles, to improve the general posture and not only the growth of the maxillaries.

Taking the above into consideration, we thought it opportune to intervene in skeletal Class II anomalies before the age of peak growth, until now considered the most suitable for solely activating condylar growth.

Pre-Orthodontic Position Trainer

It was decided to initiate Class II orthopaedic therapy not only at an earlier age, but also aiming to correct functional problems concerning soft tissues, such as lingual malposition, the centripetal thrust of lips and cheeks, as well as oral respiration and bruxism. To this aim, our attention was drawn to the Pre-Orthodontic Position Trainer (*fig. 1*), a functional device usable in children from the age of four to ten years and recommended for correcting:

- the interposition of lips between dental arches;
- atypical swallowing;
- the centripetal thrust of cheeks upon the dental arches;
- to discourage oral respiration;
- to avoid bruxism;
- to favour the action of the external pterygoids and thus encourage the active push of the mandible.

Therefore, the trainer encourages transversal bone growth (7, 11) by acting as a “shield” for the cheeks; it brings about muscular relaxation and protection of teeth and articulations from bruxism, by virtue of the “bite effect”. It determines the correction of skeletal Class II thanks to active mandibular forcing and by distancing the lower lips from the dental alveolar arch it prevents malpositioning of the

tongue and lower lip during swallowing, thus solving the associated dental open bite. It also promotes nasal respiration.

Material and Methods

Clinical Cases

Six children have been treated, four boys and two girls, ranging in age from four years and nine months to nine years and one month. Three children, affected with skeletal Class II, dental alveolar open bite, lingual malposition, atypical swallowing, non-obligatory oral respiration, were classified as Group A. Three children, displaying skeletal Class II, First Division, deep dental alveolar bite, bruxism and non-obligatory oral respiration, were classified as Group B.

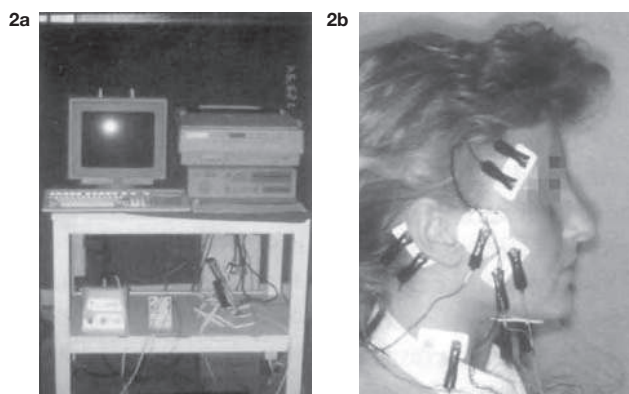
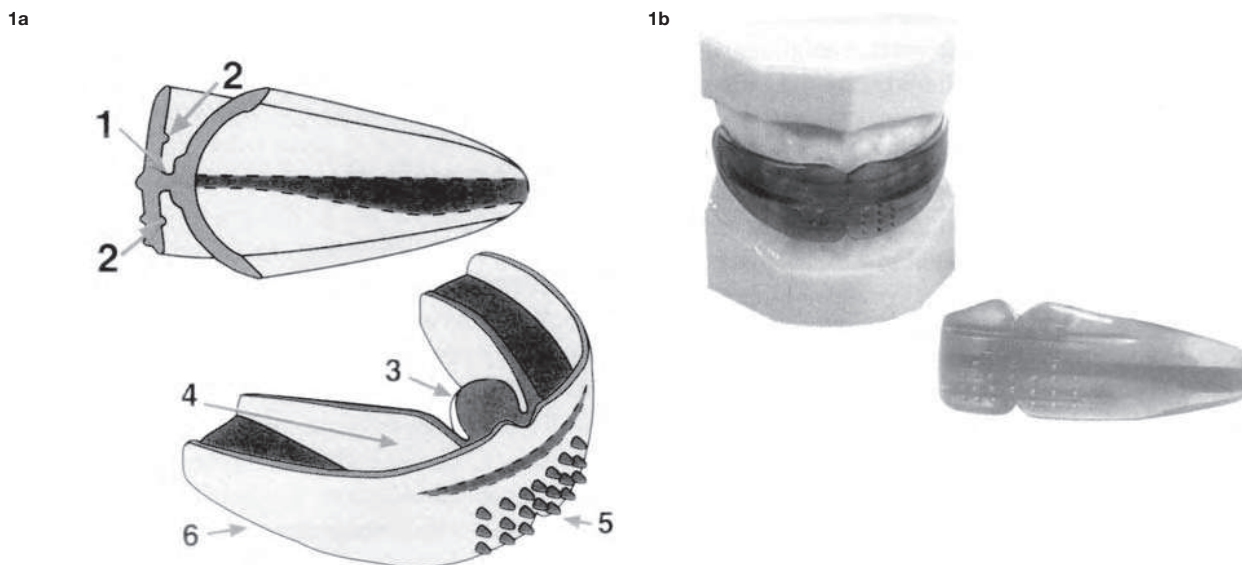
Diagnostic Criteria

The following were used as diagnostic criteria:

- 1) Standard objective examination, as at the screening visit adopted for the sixth year of age
- 2) Orthopantomography, latero-lateral telero-diography of the cranium and radiography of the wrist and hand to determine skeletal age, according to Gianní (6).
- 3) Electromyography (*fig. 2*). Recourse to a surface electromyography (3) permits the scrutiny of muscular function through the recording of electrical potentials generated by the simultaneous contraction of a number of muscle cells, defined as the potential of the motor unit. Every change in nerve or muscle fibres induces a change of that potential of the motor unit. Studies of experimental and clinical electromyography have demonstrated a linear relationship between the tension of a muscle in isometric contraction and the voltage produced. This voltage is proportional

Fig. 1a, b - Pre-Orthodontic Position Trainer: 1) guide for tooth alignment; 2) protection against malposition of lips and cheeks; 3) guide for the proprioceptive localization of the tongue; 4) protection against lingual malposition; 5) lip bumper; 6) double groove into which the teeth can be placed while lips are closed to prevent oral respiration. Also gives protection in cases of bruxism.

Fig. 2a, b - Surface electromyography.



to the tension of the muscle and also to the number of motor units called into play. It thus follows that the voltage measurement derived from one muscle represents a reliable index relating to the efficiency of that muscle or, more precisely, of the number of motor units called upon by that muscle to obtain a contraction. As muscle fatigue reduces the contractile efficiency of the motor units, the

fatigued muscle must recruit additional motor units to perform the same amount of work, thus producing additional current. Also, muscles in spasm (pathological isometric contraction) recruit an increased number of motor units because the fibres in spasm are not available for a physiological isotonic contraction.

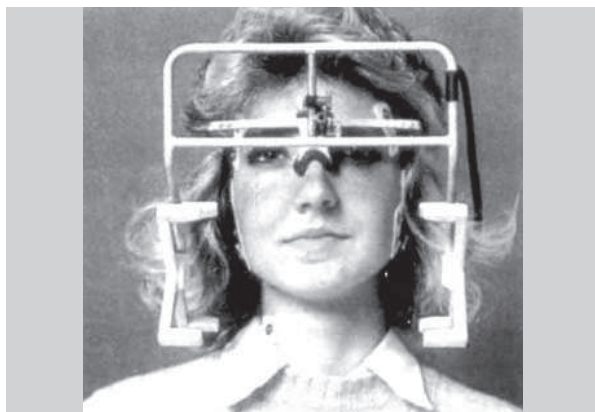
The electromyography employed consists of an eight-channel preamplifier, with filters to isolate the patient from possible current dispersions through the power supply. The channels are connected to corresponding cutaneous electrodes thus enabling the simultaneous recording of the electrical activity of four or eight muscles (masseter, anterior and posterior temporals and digastrics). Furthermore, a main computer with microprocessor is capable of converting the data relative to the electrical activities of each muscle explored from analogue to numeric. A printer provides a hard copy of the data in both graphic and numeric form. Electrical potentials are gathered by

Fig. 3 - Kinesiograph

Fig. 4 - Rhinomanometer

Fig. 5 - Stabliometric Platform


3



4



5



means of adhesive electrodes using an electroconductive gel. The methodology described is derived from that structured by Jankelson (9, 10).

4) Kinesiography with the kinesiograph interfaced to the electromyograph (4,9) (*fig. 3*). The specialised software used is capable of evaluating both the muscular condition and the kinematics of the patient's mandible. It is specifically used to investigate the patient's mandible and at the same time to evaluate the ideal trajectory of myocentric occlusion (ideal physiological occlusion that occurs in the absence of muscular spasm). The kinesiograph can measure movements in aperture, closure, laterality, protrusion and retrusion of the mandible, in the three spatial planes. It can also allow the study of velocity by exploring the principle of magnetic fields. To this aim, a small magnet is secured with special adhesive at the level of the central inferior incisors and made to act within a preset magnetic field. Magnetic field variations, caused by the magnet following the movement of the mandible, are recorded by sensing equipment secured around the patient's face. The millimetre graduated screen of an oscilloscope displays a

trace corresponding to the movement of the magnet in the preset magnetic field, allowing the localization of the incisive mandibular point. Through a kinesiographic examination, it is possible to assess dysfunctions, record the ideal neuromuscular occlusion and the discrepancy between the latter and the normal centric occlusion, always in adherence with Jankelson's indications (9, 10).

5) Rhinomanometry (2, 6, 8) basal and after exertion to distinguish obstructions of an anatomic nature from those of inflammatory nature (*fig. 4*).

6) Stabilimeter readings (1) with open eyes, with closed eyes and during deglutition on stabilimeter support (*fig. 5*).

7) Measurement of intercanine cusps (cusp to cusp) and intermolar cusps (from mesiobuccal cusp to the cusp of the first molars) of the upper arch (7, 11).

Therapeutic Methodology

The *Pre-Orthodontic Position Trainer* was the appliance used.

For Group A the soft "blue" type, for Group B the hard "red" type, but not used in succession,

as dental alignment was not sought as recommended by the manufacturers. Dental alignment does not concern us during this therapeutic phase. Therapy was carried out for a year, with the appliance worn all night and afternoon for an overall total of sixteen hours per day. An additional series of simple myotherapy exercises repeated ten times, with the *Pre-Orthodontic Position Trainer* fitted, were carried out in the morning, afternoon and evening. The exercises consisted of:

- 1) positioning of the tip of the tongue on the lingual support of the appliance, closing lips and swallowing while holding the appliance in place;
- 2) with the tongue still in the position described above, closing the lips and breathing through the nose;

Results

Diagnosis

The following observations can be extrapolated at diagnostic level:

- 1) Scan 9 in electromyography displays that Group A shows, at rest, higher potentials in temporals than in the masseters and reduced electrical activity in the masseters in absolute values, thus hypotrophic. Scan 11 shows, during functional activity (alternate clenching and relaxation of the mandible in habitual occlusion, followed by the same actions on cotton rolls), a low electrical output but with sufficient permanence in time. Electrical output is greater on the rolls, a sign of altered vertical dimension. Group B has typically, and here more markedly, an inversion of electrical values with a predominance of the temporals over the masseters, that however have normal electrical output at nominal values, thus

normotrophic, and an equal force on both the cotton roll and in habitual occlusion, a sign of free interocclusal space not being correct.

- 2) The kinesigraphic exam highlights a verticality defect, evident in Group B, with loss of free interocclusal space.

- 3) Rhinomanometry shows a scarcely significant behaviour, with normal patency or modest reduction of patency of the nasal fossae in all cases, but marked in one. However, improvement occurred during the stress test showing, in this case, the absence of actual anatomic obstructions, but only problems of an inflammatory nature. Also with reference to case histories, previous inflammatory episodes of the upper respiratory tract are found, particularly in children between the years of three and seven, coincident with school age.

- 4) The stabilimeter exam does not reveal specific pathological alterations of the overall posture, except in one case, where changes seemed attributable to the position of the mandible. However, in all cases, a certain non-specific difficulty to maintain vertical forces on the projection of the centroid are noticed and a wide and irregular bundle of oscillations is displayed, meaning the centre of the mass is somewhat lateralized.

Therapy

At therapeutic level in both groups, normalization of the dental skeletal Class, with improvements of the skeletal class, with average reduction of the ANB angle of 1.5°. In Group A closure of the dental open bite is achieved, while Group B shows a slight improvement of the overbite. The dento-skeletal improvement appears more noticeable in Group A cases with open bite due to lingual malposition. The electromyography emphasizes, for Group A, a normalization of values in Scan 9, with an increase of potentials

generated by the masseters and an improvement of contraction force during habitual occlusion as compared to the contraction on the cotton roll of Scan 11.

Scan 20 shows normalization of the function of the suprahyoid muscles used in physiological deglutition, with symmetric potentials within the norm of absolute values. Group B shows a reduction of potentials generated by the temporals and a normalization of the relationship between temporals and masseters. The physiological prevalence of the latter is thus proof of results obtained on bruxism.

The kinesiographic exam of Group B displays normalization of interocclusal free space.

Rhinomanometrics do not show noticeable improvements. Stabilimeter readings show improvement in maintaining the baricentre position on the vertical plane for both groups. Measurement of diameters of intercanine and upper intermolar shows an increase in the latter.

Discussion

The clinical and instrumental evaluation of the two groups of patients confirms that therapy of Class II patients having soft tissue dysfunctions or parafunctions show improvement after using the *Pre-Orthodontic Position Trainer* for one year. The following is achieved:

- 1) Normalization of the muscular function, evident and complete in both Group A and B, together with resolution of atypical deglutition and control of bruxism;
- 2) Improvement of the dental structure. Evident and significant in Group A with closure of open dental bite. Less marked in Group B with reduced aperture of bite and improvement in tooth crowding;
- 3) A modest result at skeletal level, median reduction of the ANB angle of 1.5°, comparable in Groups A and B;

4) Unchanged patency in the nasal fossae, but improved aptitude towards nasal respiration with respect to non-obligatory oral breathing;

5) Influence upon the overall body posture: improved capability to maintain the projection of centre of mass on the vertical;

6) Intercanine and intermolar diameters: increased only in the intermolars with modest improvement of crowding of frontal teeth, when of a significant degree.

Conclusions

This study is a preliminary report the purpose of which is to clinically evaluate the therapeutic efficacy of the *Pre-Orthodontic Position Trainer*. The subjects analysed here, after further Class II orthopaedic therapy with rapid expansion of the palate and mandibular impulsion, will serve as cases for comparison with controls treated only with Class II orthopaedics and not preceded by the *Pre-Orthodontic Position Trainer* phase. The clinical results illustrated above lead us to believe that it would be correct to bring forward by a year the therapy specifically aimed at eliminating those dysfunctional and parafunctional factors of the soft tissues that can interfere with the mandibular growth and promote correct deglutition, correct nasal respiration and elimination of pathological muscular contractures. The device is well tolerated by small patients, does not require collaboration different from that necessary for a common brace and requires fewer speech therapy sessions. As a result, the trainer delivers patients ready to start Class II therapy, free from muscular dysfunctions or parafunctions, already accustomed to a prolonged and active posture of the mandible. Furthermore, this intervention would seem

appropriate in preventing abnormal postural attitudes of the face typical of skeletal Class II.

Clinical Cases

Case number 1 (Group A)

Male patient MM of seven years and eight months, of skeletal Class II (*fig. 6a*), ANB angle of 11.2° (*fig. 6b*), infantile deglutition, lingual malposition, open dental bite with a OVB of -0.7 mm and moderate dental crowding.

The electromyography shows (*Fig 6d*) a reduction of the contractile force of the masseters, displaying a hypotrophic nature, and an improved recruitment of fibres during contraction on the cotton roll with respect to that in habitual occlusion.

Rhynomanometrics show normal patency of the nasal fossae (*fig. 6e*), though in the presence of oral respiration, is interpreted as an abnormal habit following repeated episodes of inflammation of the upper respiratory track in the past.

Stabilimeter output (*fig. 6f*) measurements are within the normal range although difficulty is shown in keeping the projection of the centre of the mass on the vertical.

Therapy lasted from December 1999 to February 2001 and was carried out with the *Pre-Orthodontic Position Trainer* (colour blue, soft) (*fig. 1*) worn for about sixteen hours a day and in association with myotherapy exercises.

Final examinations show a more harmonious profile (*fig. 6a*), reduction of ANB to 9.8° (*fig. 6b*), gain of the OVB up to 0.6 mm, closure of the dental open bite and improvement of the molar and canine class (*fig. 6c*).

Electromyography displays in Scan 9 normalization of the absolute values of the potentials generated by the masseters, which also appear normotrophic, with physiological dominance of

the masseters over the temporals. Scan 11 reveals normalization of the capability of recruitment of fibres in contraction during habitual occlusion, force that now prevails over that of contraction over the cotton roll (*fig. 6d*). The suprahyoids, and particularly the digastrics, appear symmetrical with normal potentials in absolute value in Scan 20. This corresponds to attaining a normal physiologic deglutition.

The rhinomanometric examination appears to be substantially unchanged except for a very slight improvement in the patency of the nasal fossae (*fig. 6e*). Stabilimetry reveals that the centre of the pressor force of the feet can be superimposed on the centroid of vertical forces (*fig. 6f*). Measurements on the plaster models show an increase only of the upper intermolar diameter of 1.5 mm, with that of the upper intercanine unvaried.

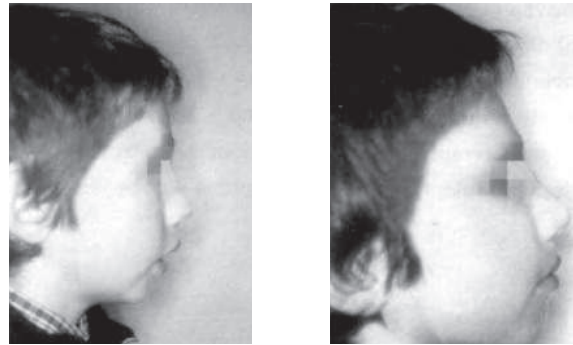
Case number 2 (Group B)

Female patient GG, of nine years and one month, of skeletal Class II (*fig. 7a*), ANB angle of 6° (*fig. 7b*), deep dental bite with OVB equivalent to 6 mm, marked crowding borne by the incisors (*Fig 7c*) and bruxism. The electromyography shows in Scan 9 predominance of hypertonic temporals over the masseters, also hypertonic, a situation compatible with deep bite and bruxism, while Scan 11 shows that biting on the cotton roll generates an increased electrical output greater than the norm and equal to the electrical output during closure in habitual occlusion. This denotes incorrect free interocclusal space, with a possible loss of free interocclusal space. Predominance of the temporals remains (*fig. 7e*). Rhinomanometry shows obvious obstruction of flow with reduced patency of both nasal fossae (*fig. 7f*).

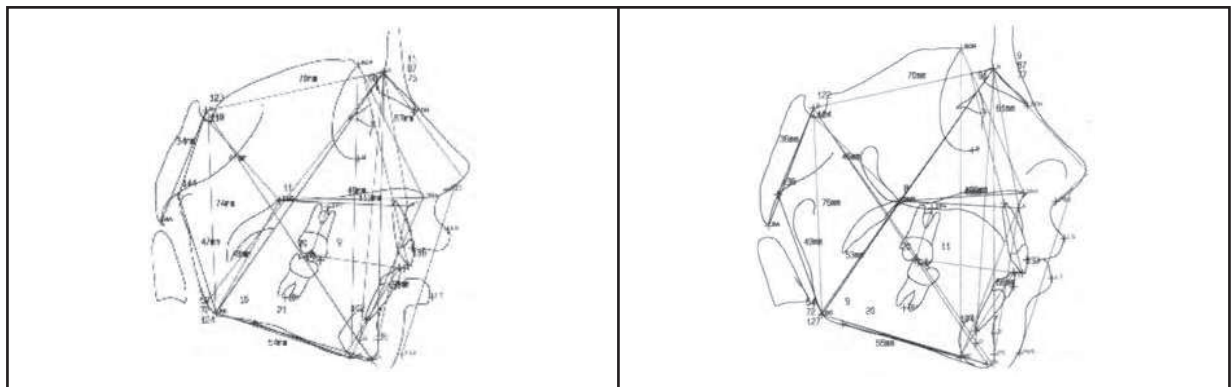
Stabilimetry shows irregularity in the ball of the foot with difficulties in maintaining the

Fig. 6a-f - Patient MM. a) profile before and after therapy; b) cephalometric diagram before and after therapy; c) overjet and dental overbite before and after therapy; d) electromyography before therapy, Scan 9 and Scan 11; and after therapy, Scan 9, 11; e) rhynomanometry before and after therapy; f) stabilimeter measurements before and after therapy.

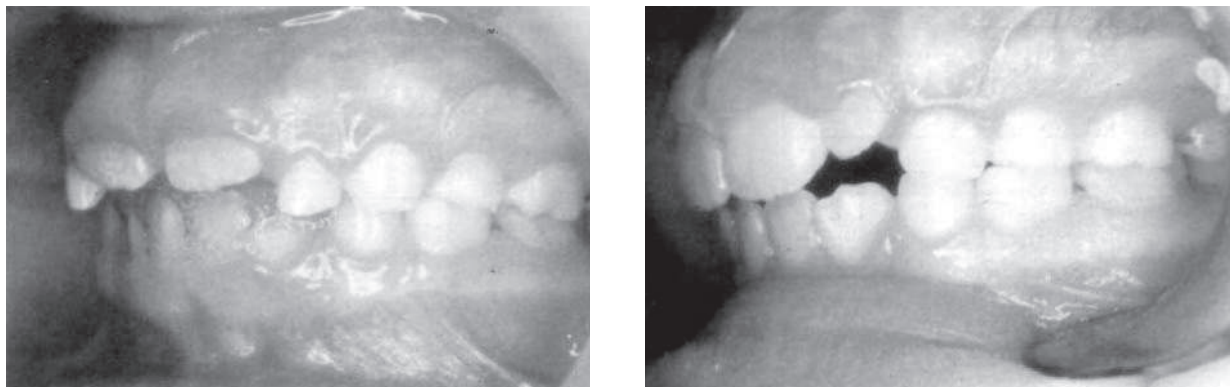
6a



6b



6c



6d

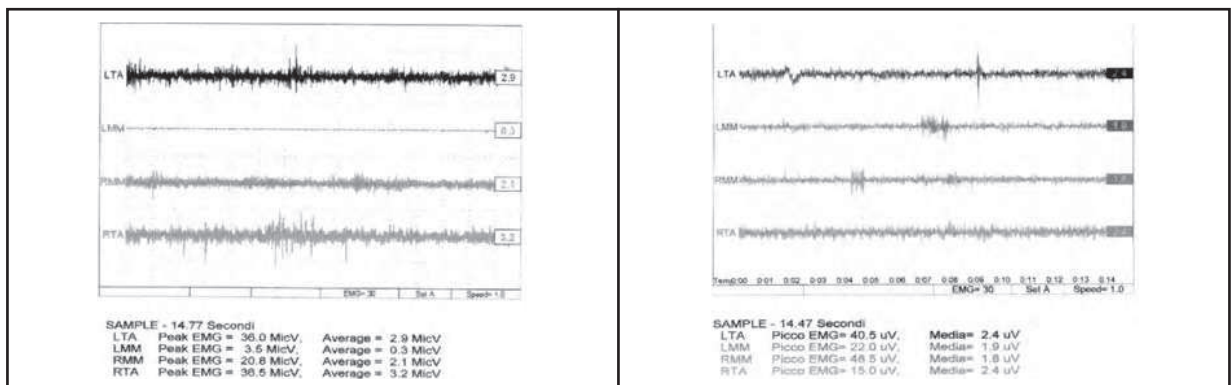




Fig. 6a-f - Patient MM. a) profile before and after therapy; b) cephalometric diagram before and after therapy; c) overjet and dental overbite before and after therapy; d) electromyography before therapy, Scan 9 and Scan 11; and after therapy, Scan 9, 11; e) rhynomanometry before and after therapy; f) stabilimeter measurements before and after therapy.

6d



6e



6f

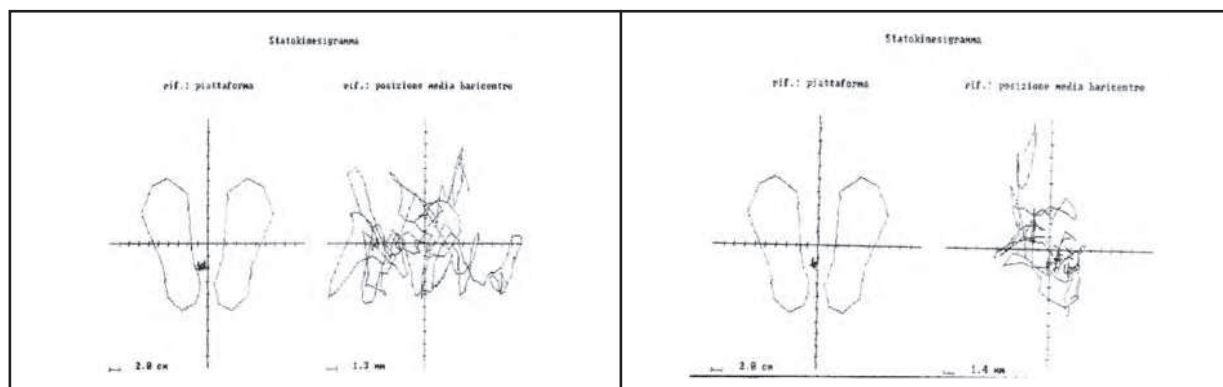


Fig. 7a-f - Patient GG. a) profile before and after therapy; b) cephalometric diagram before and after therapy; c) overjet and overbite before and after therapy; d) electromyography before and after therapy; e) rhynomanometry before and after therapy; f) stabilimeter measurements before and after therapy.

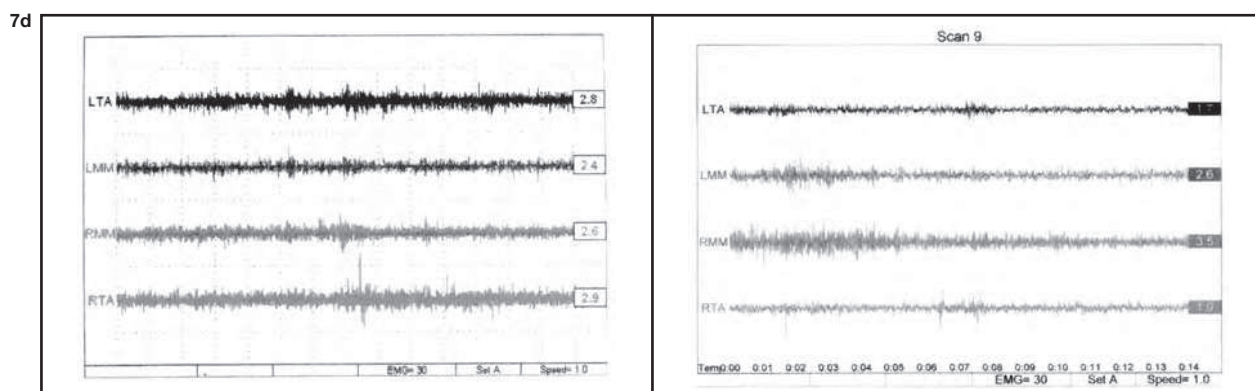
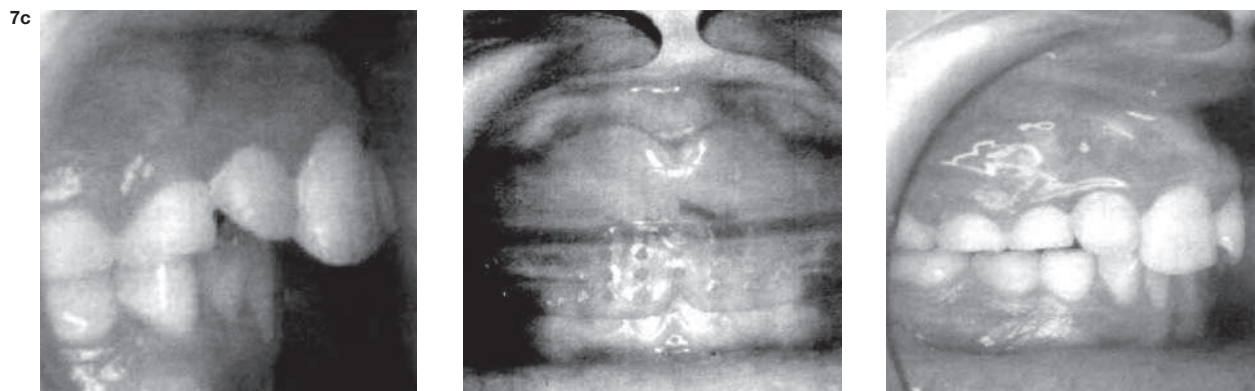
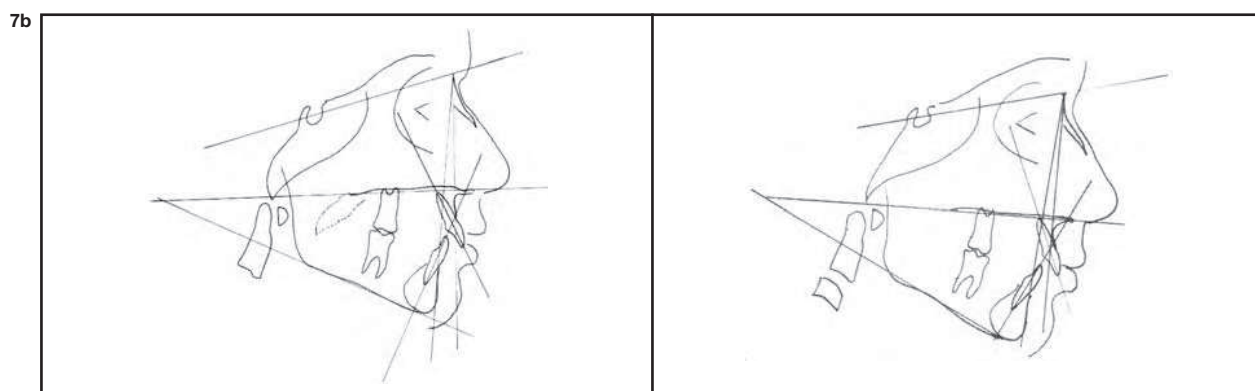
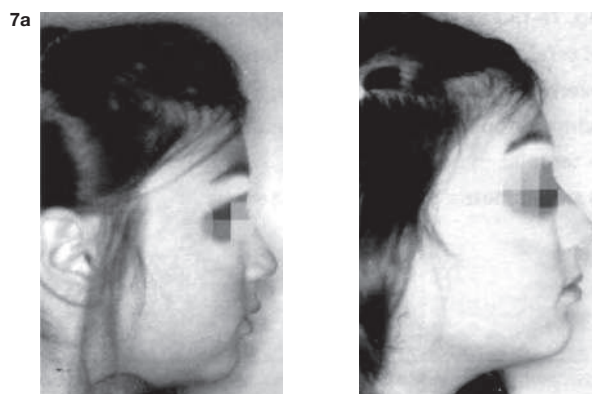
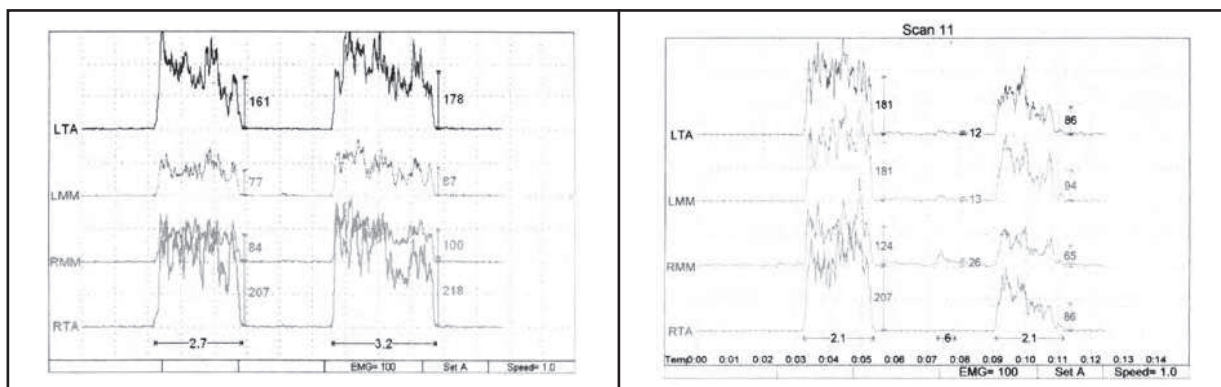
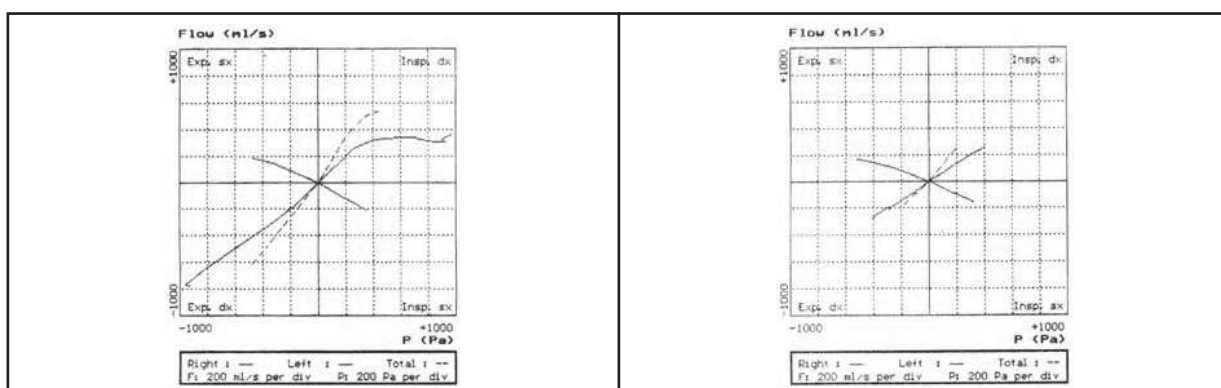


Fig. 7a-f - Patient GG. a) profile before and after therapy; b) cephalometric diagram before and after therapy; c) overjet and overbite before and after therapy; d) electromyography before and after therapy; e) rhynomanometry before and after therapy; f) stabilimeter measurements before and after therapy.

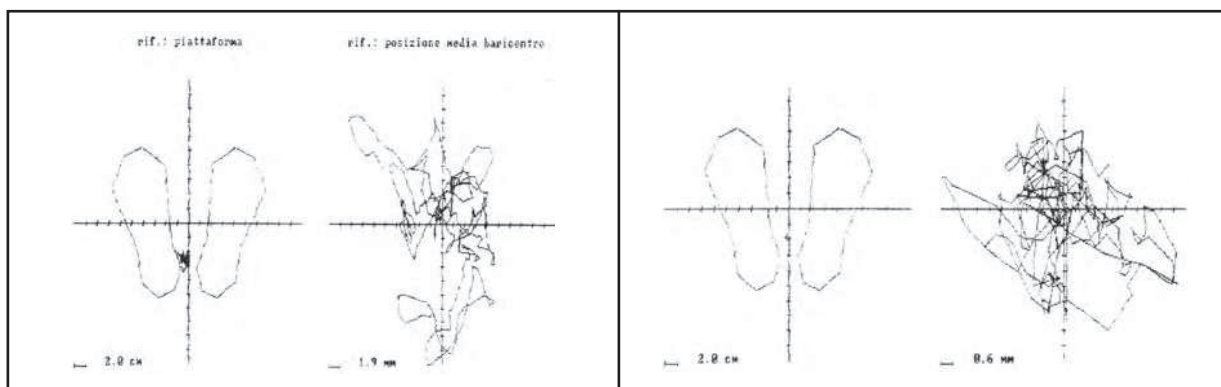
7d



7e



7f



projection of the centroid of the mass on the vertical (fig. 7e) even though the results are within the norm.

Therapy lasted from September 1999 to March 2001 using the *Pre-Orthodontic Position Trainer* (colour red, hard, for bruxism) worn for sixteen hours a day, together with specific myotherapy exercises.

Final examination shows: improvement of skeletal Class II with more regular profile (fig. 7a), and reduction of angle ANB to 5° (fig. 7b).

Improvement of the occlusal relationship at canine and molar level, but modest effect on crowding and reduction of the OVB to 5 mm (fig. 7c).

Electromyography (fig. 7d) shows in Scan 9 the normalization of the temporal/masseter relationship, with physiologic prevalence of the masseters. This suggests that control over bruxism has been obtained. Scan 11 displays a drop in closure force upon the cotton roll as compared to that needed for habitual occlusion, indicating a probable recovery of physiologic interocclusal free space.

Rhinomanometry does not show improvements (fig. 7e).

Stabilimetry demonstrates perfect centering of the projection of the centroid vertical forces upon the vertical plane, in perfect coincidence with the centre of pressure of the feet (fig. 7f).

Measures on plaster models do not show an increase of either the intercanine or the intermolar diameter and no improvement of dental crowding is apparent.

Summary

The effects of the Pre-Orthodontic Position Trainer on the stomatognathic system in Class II with soft tissue dysfunctions or parafunctions are analysed. The therapy, lasting one year,

precedes and prepares for normal Class II orthopaedic therapy and is carried out at an earlier age coincident with the pre-pubertal growth peak. Ideal age is between four and nine years of age.

The results of the treatment are analysed by means of clinical, radiological, electromyographical, kinesiographical, stabilimetric, rhyno-manometric evaluations and measurements of arch diameters using plaster models. The pilot cases, described and commented on, show the efficacy of carrying out a myofunctional therapeutic approach on skeletal Class II subjects at an early age.

Key Words

Skeletal Class II

Early treatment

Dysfunctions of soft tissues and parafunctions

Bibliography

1. Barresi G, Nastro Siniscalci R, Micalizzi A et alia. (La postura stabilometria in pazienti con placche interocclusali.) Stabilimetry posture in patients with interocclusal plaques. Dental Cadmos 2001; 2: 65-7.
2. Farronato G, Giannì AB, Arnelli M et alia. (Rinomanometria posteriore attiva bilaterale simultanea. Otorinolaringologia.) Simultaneous bilateral active posterior rhinomanometry. Otorhinolaryngology. 1989; 6: 39.
3. Ghiglione V, Garagiola U, Mori P (Ruolo della indagine elettromiografica nella diagnosi e terapia ortodontica.) Role of electromyography in orthodontic diagnosis and therapy. Doctor Os 1995; 6: 55-63

4. Ghiglione V, Ciancio P, Maspero C. (Importanza della computerizzazione in ortodonzia.) Importance of computers in orthodontics. *Doctor Os* 1998; 9: 25-30.
 5. Giannì E. (La nuova ortognatodonzia.) Padua: Piccin, 1980, 1985; Vols. 1, 2.
 6. Giannì E, Farronato GP, Rusca M, et alia. (Gestione computerizzata del servizio di rinomanometria.) Computerised management of rhinomanometric facility. *Mondo Ortodontico* 1987; 6.
 7. Gibbs SL, Hunt NP. Functional appliances and arch width. *Br J Orthod* 1992; 19: 117-25.
 8. Gross AM et alia. Rhinomanometry and open mouth posture in young children. *Am J Orthod Dentofac Orthop* 1993; 103: 526.
 9. Jankelson B, Swan CW, Crane PF. Kinesiometric instrumentation a new technology. *JADA* 1975; 90: 384.
 10. Jankelson B. (Aspetti della posizione occlusale sulla fisiologia e sulle disfunzioni della muscolatura mandibolare. La Clinica Odontoiatrica del Nord America.) Effects of the occlusal position on physiology and on mandibular muscular dysfunctions. *The Clinic of Odontology of North America*. 1980; 1: 3.
 11. Owen AH. Morphologic changes in the transverse dimension using the Frankel appliance. *Am J Orthod Dentofac Orthop* 1983; 83: 200-17.
 12. Petrovic A, Stutzmann J. (Le muscle pterygoidien externe et la croissance du condyle mandibulaire. Recherches experimentales chez le jeune rat.) The external pterygoid and development of the mandibular condylar. *Experimental research among young rats*. *Orthod Franc* 1972; 43: 271-8.
 13. Petrovic A, Stutzmann J. (Stimolazione di crescita della mandibola umana indotta ortopedicamente. Nuovi approcci alla decisione clinica) Orthopaedically induced growth stimulation of the human mandible. New approaches to the clinical decision. XIV Congresso Sido Internazionale Venezia, 22-25 ottobre 1987.
 14. Quadrelli c, Ghiglione V, Marchetti C. (Relazione tra postura, disfunzioni dei tessuti molli dell'apparato stomatognatico, respirazione e occlusione nel trattamento precoce delle II Classi scheletriche.) Relationships between posture, dysfunctions of the soft tissues of the stomatognathic apparatus, respiration and occlusion in early treatment of skeletal Class II. Congress "Occlusion and Posture; new Trends and New Problems". Milan June 2001.
 15. Quadrelli C, Ghiglione V, Gheorghiu M et alia. (Relazione tra postura, disfunzione dei tessuti molli dell'apparato stomatognatico, respirazione e occlusione nel trattamento precoce nelle II Classi scheletriche.) Relationships between posture, dysfunction of soft tissues of the stomatognathic apparatus, respiration and occlusion in the early treatment of skeletal Class II. XVI National Congress Sido, Genoa 26-27 October 2001.
 16. Ung N, Koenig J, Shapiro PA et alia. A quantitative assessment of respiratory patterns and their effects on dentofacial development. *Am J Orthod Dentofac Orthop* 1991; 98.
- Received in editorial office October 2001*
Carlo Quadrelli
Via Bixio 4
21013 Gallarate (VA)
tel. 0331 777261 - 305422
fax. 0331 777261
e.mail: c.quadrelli@libero.it